

## GUIDELINES AND RECOMMENDATIONS

# A minimum dataset for a standard adult transthoracic echocardiogram: a guideline protocol from the British Society of Echocardiography

Gill Wharton\*, Richard Steeds<sup>1†</sup>, Jane Allen, Hollie Phillips<sup>2</sup>, Richard Jones<sup>3</sup>, Prathap Kanagala<sup>4</sup>, Guy Lloyd<sup>5</sup>, Navroz Masani<sup>6</sup>, Thomas Mathew<sup>7</sup>, David Oxborough<sup>8</sup>, Bushra Rana<sup>9</sup>, Julie Sandoval<sup>10</sup>, Richard Wheeler<sup>6</sup>, Kevin O’Gallagher<sup>11</sup> and Vishal Sharma<sup>12</sup>

York Teaching Hospital NHS Foundation Trust, York, UK

<sup>1</sup>Queen Elizabeth Hospital, University Hospital Birmingham NHS foundation Trust, Birmingham, UK

<sup>2</sup>InHealth Ecotech, Hampshire, UK

<sup>3</sup>Portsmouth Hospitals NHS Trust, Portsmouth, UK

<sup>4</sup>Glenfield Hospital, Leicester, UK

<sup>5</sup>Eastbourne District General Hospital, Eastbourne, UK

<sup>6</sup>University Hospital of Wales, Cardiff, UK

<sup>7</sup>Nottingham University Hospital, Nottingham, UK

<sup>8</sup>Research Institute for Sports and Exercise Sciences, Liverpool John Moores University, Liverpool, UK

<sup>9</sup>Cardiology Department, Papworth Hospital, Cambridge, UK

<sup>10</sup>Cardiac Ultrasound, Leeds Teaching Hospitals NHS Trust, Leeds, UK

<sup>11</sup>King’s College Hospital NHS Foundation Trust, London, UK

<sup>12</sup>Royal Liverpool and Broadgreen University Hospitals, Liverpool, UK

\* (G Wharton is the lead author)

† (R Steeds is the Guidelines Chair)

Correspondence should be addressed to V Sharma  
**Email**  
vishal.sharma@rlbuht.nhs.uk

## Abstract

There have been significant advances in the field of echocardiography with the introduction of a number of new techniques into standard clinical practice. Consequently, a ‘standard’ echocardiographic examination has evolved to become a more detailed and time-consuming examination that requires a high level of expertise. This Guideline produced by the British Society of Echocardiography (BSE) Education Committee aims to provide a minimum dataset that should be obtained in a comprehensive standard echocardiogram. In addition, the layout proposes a recommended sequence in which to acquire the images. If abnormal pathology is detected, additional views and measurements should be obtained with reference to other BSE protocols when appropriate. Adherence to these recommendations will promote an increased quality of echocardiography and facilitate accurate comparison of studies performed either by different operators or at different departments.

### Key Words

- ▶ transthoracic echocardiography
- ▶ 2D echocardiography
- ▶ guidelines

## Introduction

This Guideline aims to provide a framework for performing an adult transthoracic echocardiogram (TTE) and replaces the previous minimum datasets published.

This current Guideline differs from the 2005 dataset in outlining the views and measures recommended in a fully comprehensive TTE, and in addition recognises that such



This work is licensed under a [Creative Commons Attribution-NonCommercial-NoDerivs 4.0 International License](https://creativecommons.org/licenses/by-nc-nd/4.0/).

© 2015 The British Society of Echocardiography

[www.echopract.com](http://www.echopract.com)  
Published by Bioscientifica Ltd

studies may not be performed in all circumstances. The layout proposes a recommended sequence on how to perform a comprehensive TTE.

'Minimum requirements' are depicted in bold text and identify the views and measurements that should be performed in all subjects being scanned for the first time 'recommendations' are depicted in italics and together with the minimum requirements form the basis of a comprehensive examination. Wherever possible, a comprehensive study comprising all the views and measurements in this Guideline outlined in black italics and bold font text should be performed, provided the views and measurements can be obtained reliably. It is understood that not all the measurements in the minimum requirements dataset will be performed in all follow-up studies. It is also understood that not all measurements in the minimum requirements will be performed in focused or target studies, for example check pericardial effusion.

Both minimum requirements and recommendations may only be sufficient when the echocardiographic study is entirely normal. If abnormalities are detected, additional views may be required to supplement those outlined in the dataset.

The layout has been altered to provide a visual example of the ideal image that should be acquired in each acoustic window. This is supported by text that follows a standard layout – the acoustic window and transducer position in the first column, followed by the modality to be used, measurements to be made at that location and an explanation if additional information is deemed necessary.

## A standard adult transthoracic echocardiogram

### 1. Benefits and general principles

A standardised approach to performing an echocardiogram is extremely important not only to ensure that pathology is not missed but to facilitate comparison between studies.

1.1. The intended benefits of this Guideline are:

- To support cardiologists and echocardiographers to develop local protocols and quality control programmes for an adult transthoracic study. These minimum requirements and recommendations provide a template against which studies in any department should be audited.
- To promote quality by defining a 'minimum dataset' of descriptive terms and measurements.

- To promote quality by defining a recommended dataset of descriptive terms and measurements that departments should work toward obtaining in all studies.
- To facilitate accurate comparison of serial echocardiograms performed in patients at the same or different sites.
- To facilitate the transition to digital echocardiography acquisition and reporting systems that use database (software) architecture.

1.2. There is broad agreement regarding the standard views and recordings essential in an echocardiographic examination. There is, however, no evidence-base and these recommendations and requirements represent a consensus view on the components of a complete TTE study.

1.3. It is expected that a standard echocardiogram following at least these minimum requirements will be performed in all adults when an echocardiogram is requested. This type of study is expected to make up the majority of those performed within any department, whether in the community or in hospital.

It is recognised that focused studies may be appropriate in some circumstances agreed locally. Focused TTE can either mean focusing on major abnormalities predominantly in an urgent clinical situation, e.g. pericardial effusion, or focusing on a particular aspect of the heart, e.g. longitudinal monitoring of left ventricular function. The skill level required for such studies is very high and it is expected that the patient will previously have had a full-standard TTE before monitoring commences or after an emergency assessment has been completed. Such studies should be clearly identified as focused studies and are not covered by this Guideline.

1.4. When the condition or acoustic windows of the patient prevent the acquisition of one or more components of the minimum dataset, or when measurements result in misleading information (e.g. off-axis measurements) this should be stated.

It is recommended that any study is accompanied by a statement regarding the image quality achieved: good/fair/poor.

1.5. Unless the physical condition of the patient prevents transfer, all TTEs should be performed in a suitable environment, with optimal facilities to obtain the highest quality ultrasound images, including lighting, space and imaging couches, whilst guaranteeing patient privacy.

These facilities demand – except in exceptional circumstances – that echocardiography is delivered in an appropriately equipped department that satisfies the requirements of the BSE Departmental Accreditation process. This ensures optimum conditions for a detailed study, reduces the risk of musculoskeletal disorders for echocardiographers (<http://www.hse.gov.uk/health-services/management-of-musculoskeletal-disorders-in-sonography-work.pdf>), and may reduce the risk of hospital-acquired infection. When portable echocardiography has to be performed at the bedside, the requirements of the minimum dataset must be met.

## 2. Identifying information

The images acquired should be clearly labelled with patient identifiers, including the following:

- Patient name.
- A second unique identifier such as hospital number or date of birth.
- Identification of the operator, e.g. initials.

## 3. Electrocardiogram (ECG)

An ECG should be attached ensuring good tracings to facilitate the acquisition of complete digital loops. Loops should be examined and adjusted accordingly in order to ensure a clear representation of the image acquired.

## 4. Height/weight/haemodynamic variables

Qualitative and quantitative evaluation of chamber size and function is a major component of every echocardiographic examination. Chamber dimensions may be influenced by age, gender and body size. Therefore, consideration should be given to the use of referenced ranges indexed to height or body surface area. In addition, velocities measured using Doppler should take account of pulse rate and blood pressure. No recommendation is made to the routine use of indexed measurements, but facilities should be available to sonographers to measure height, weight, pulse rate and blood pressure at the time of an echocardiogram.

## 5. Duration

The average time required for performance and reporting of a fully comprehensive TTE following these recommendations is considered to be 40–45 min, although it is

understood that some studies may take longer whilst others may take less time. The time taken for a standard TTE should include time to complete a report, and should also take into account the time taken for patient preparation.

## 6. Report

No standard TTE is complete until a report is released and is made available to the referring individual. The majority of studies performed in a department should be reported immediately on completion and a report available on discharge of a patient from the echocardiography facility.

It is recognised that there are times when a review of images and further consideration is required, for example when the individual performing the scan does not hold proficiency accreditation and the scan requires review before release, although this should be done as soon as possible.

## 7. Chaperones

A standard TTE is not considered as an intimate examination, but performance still requires patient sensitivity. Chaperones should not usually be required for standard TTE; however, for all TTE studies, patients should be offered a gown.

Echocardiography departments should send out an information leaflet with any appointment. This should include a statement that a relative or friend could accompany the patient to act as a chaperone during the study if preferred. If a friend or relative cannot attend, the leaflet should include an offer to provide a chaperone if requested by the patient. This leaflet should either offer a chaperone by mutual arrangement or, if facilities and personnel allow, a chaperone to be provided on request when the patient arrives.

A notice should be displayed in the Echocardiography department where it can be seen by patients repeating the offer of a chaperone if requested. In practice, it is expected that the majority of patients would not need or have a chaperone.

## The minimum dataset

The minimum dataset and recommended sequence for a standard TTE is shown in [Table 1](#). The minimum requirements are depicted in bold text and recommendations in italics. The minimum requirements are also summarised in [Appendix 1](#).

**Table 1** Minimum dataset for transthoracic echocardiography. Minimum requirements are depicted in bold text and identify the views and measurements that should be performed in all subjects being scanned for the first time provided that they can be obtained reliably. However wherever possible a comprehensive study should be performed. Recommendations are depicted in italics and together with the minimum requirements form the basis of a comprehensive examination.

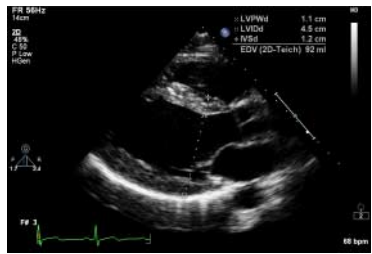
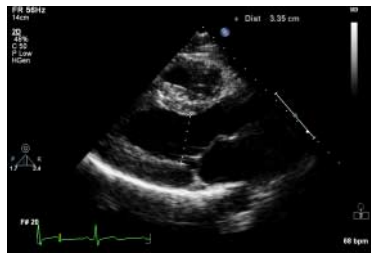

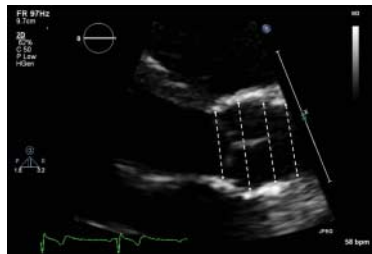

View (modality)	Measurement	Explanatory note	Image
PLAX (2D)	<b>LVIDd/s, IVSd, LVPWd (either 2D or M mode measurement)</b>  <b>LA size (end ventricular systole) (either 2D or M mode measurement)</b>	<b>LV cavity size, wall thickness, radial function</b>  <b>LA appearance</b>  <b>MV leaflet and annulus appearance and function: thickness, mobility, calcification, commissural fusion, sub-valve apparatus</b>	
PLAX (2D)		<b>AV/LVOT appearance and function</b>	
PLAX (2D)	<i>Proximal RVOTd</i>		
PLAX (2D)	<b>Sinus of Valsalva (either 2D or M mode measurement, inner edge to inner edge at widest diameter)</b>  <i>Annulus, ST junction, proximal ascending aorta (inner edge to inner edge, at widest diameter)</i>	<b>Aortic root – appearance and function</b>	
PLAX (2D)	<i>LVOT for AV area/SVol in mid systole</i>	<i>Approximately same location as the PW sample volume in the A5C view (measured in the LVOT up to 1 cm from the annulus)</i>	



Table 1 Continued

View (modality)	Measurement	Explanatory note	Image
PLAX RV inflow (CW)	TR $V_{max}$	If good alignment with jet	
PLAX RV outflow (2D)	Distal RVOT	RVOT, PV, main PA, LPA	
PLAX RV outflow (CFM)		RVOT, PA, PS, PR Optional to PSAX	
PLAX RV outflow (PW)		Optional to PSAX	
PLAX RV outflow (CW)		Optional to PSAX	
PSAX outflow (2D)	Proximal RVOT diameter	RVOT (function) AV – appearance and function LA/atrial septum TV – appearance and function	
PSAX outflow (2D)	PV annulus, main PA	PV, main PA	



Table 1 Continued

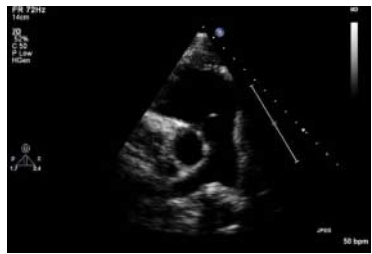
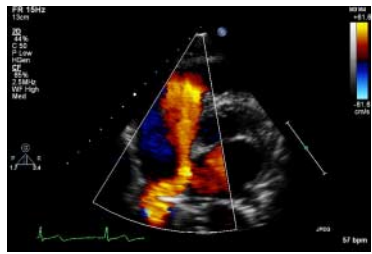
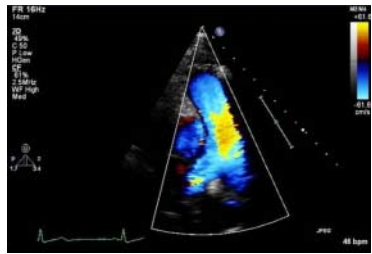
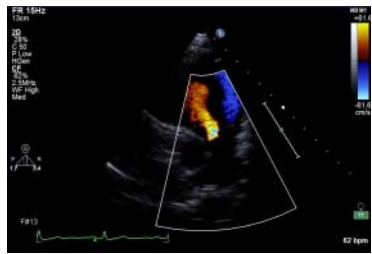
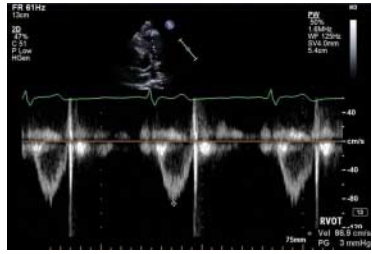
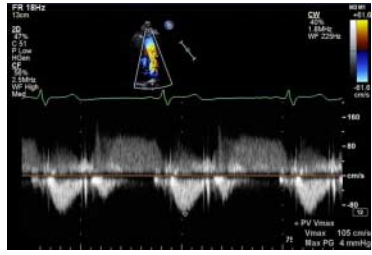
View (modality)	Measurement	Explanatory note	Image
PSAX outflow (2D)		Proximal branch PA's	
PSAX outflow (CFM)		Ao/LA Atrial septum IVC TV inflow, TR	
PSAX outflow (CFM)		PA, look for abnormal colour flow	
PSAX outflow (CFM)		RVOT (PR)	
PSAX outflow (PW)	$V_{max}$ $V_{mean}$ $VTI$	RVOT (just proximal to PV)	
PSAX outflow (CW)	$V_{max}$ $V_{meanPHT}$	PA PR density and contour of signal	

Table 1 Continued



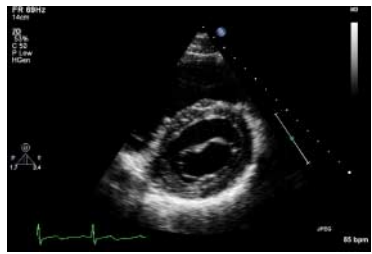
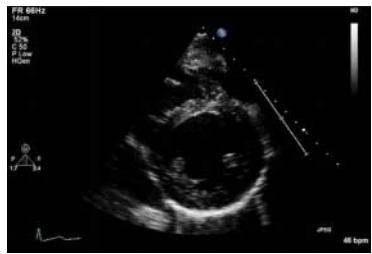
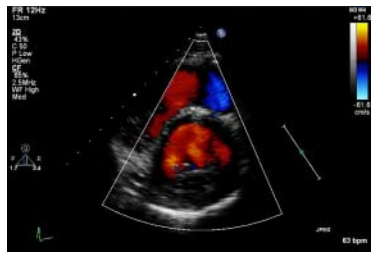
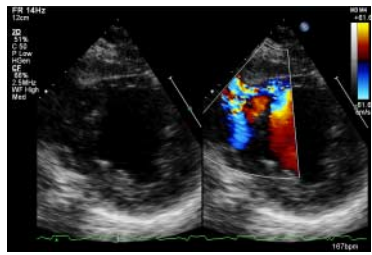
View (modality)	Measurement	Explanatory note	Image
PSAX outflow (CW)	PR $V_{max}$ (end diastolic PA pressure)	End diastole	
PSAX outflow (CW)	PR $V_{max}$ (mean diastolic PA pressure)	Early diastole	
PSAX Base (2D)		MV leaflet and annulus: – appearance and function – thickness, mobility, calcification, commissural fusion, sub-valve apparatus	
PSAX mid (2D)		Sweep beam from base to apex  Radial systolic function/ regional wall motion abnormalities  Integrity of ventricular septum	
PSAX (CFM)		Sweep beam from base to apex  Integrity of ventricular septum	
PSAX (CFM)		VSD's (congenital/post infarct)	



Table 1 Continued

View (modality)	Measurement	Explanatory note	Image
A4C (2D)		<p>LV cavity size, wall thickness (Inferoseptum, anterolateral)</p> <p>Longitudinal and radial function:</p> <p>RWMA's (inferoseptal and anterolateral)</p> <p>MV/TV appearance and function</p> <p>Atrial septal mobility</p>	
A4C (2D)	Area/volume ( <i>should not be done if images sub optimal</i> )	<p>LV end diastolic area/volume (BSA indexed). Consider 3D volumes, unless images are suboptimal</p> <p>Consider LV opacification contrast if poor image quality</p>	
A4C (2D)		<p>LV end systolic area/volume (BSA indexed). Consider 3D volumes, unless images are suboptimal</p> <p>Consider LV opacification contrast if poor image quality</p>	
A4C (2D)	LA volume	LA size (measured at end ventricular systole and BSA indexed)	
A4C (MM)	TAPSE MAPSE	<p>TV annulus</p> <p>MV annulus</p>	





Table 1 Continued

View (modality)	Measurement	Explanatory note	Image
A2C (2D)	LV area/volume	<p>LV end diastolic area/volume</p> <p><i>Consider 3D volumes, unless images are suboptimal</i></p> <p><i>Consider LV opacification contrast if poor image quality</i></p>	
A2C (2D)		<p>LV end systolic area/volume</p> <p><i>Consider 3D volumes, unless images are suboptimal</i></p> <p><i>Consider LV opacification contrast if poor image quality</i></p>	
A2C (2D)	<p>LA area/volume (measure at end ventricular systole)</p> <p>Modified Simpsons or area length method</p>	LA size	
A2C (CFM)		LV inflow, look for abnormal colour flow	
A2C (PW)	$E, A, DT$ if not reliable from A4C	LV inflow (MV tips)	
A2C (CW)	$V_{max}, V_{mean}$ if not reliable from A4C		
A3C (2D)		<p>LV cavity size, wall thickness: function (anteroseptal and inferolateral)</p> <p>AV/LVOT appearance and function</p>	

Table 1 Continued

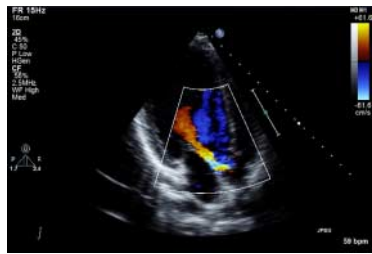
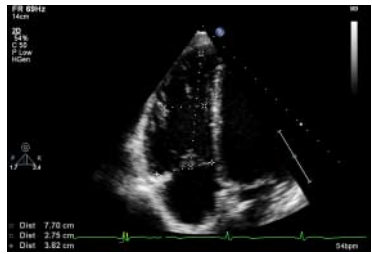
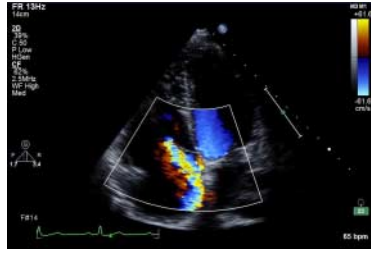
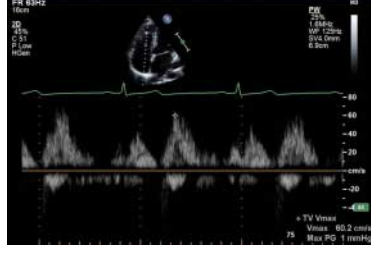

View (modality)	Measurement	Explanatory note	Image
A3C (CFM)		LVOT, LV inflow, look for abnormal colour flow	
ALAX (PW)	<i>E, A, DT, VTI if not reliable from A5C</i>	LV inflow (MV tips) LVOT	
A3C (CW)	$V_{max}$ $V_{mean}$	LV inflow	
	$V_{max}$ $V_{mean}$	LVOT	
Modified A4C (2D)	<b>RVID base (d)</b>	<b>RV cavity size and function</b>	
	<i>Mid RV diameter</i>		
	<i>RV length (base to apex)</i>		
	<i>RA area</i>	<b>RA size</b>	
Modified A4C (CFM)		TV inflow, TR	
Modified A4C (PW)	$E V_{max}$	RV inflow (TV leaflet tips)	
Modified A4C (CW)	$V_{max}$ (RV systolic pressure, PAP) TR		

Table 1 Continued


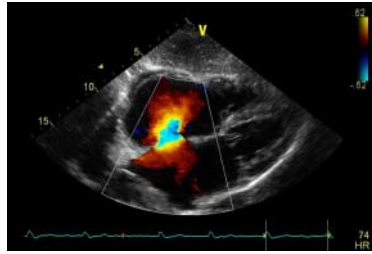

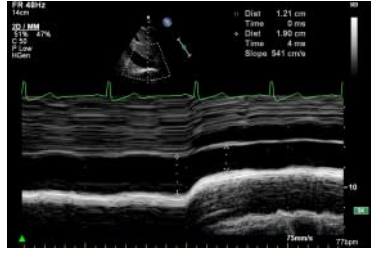

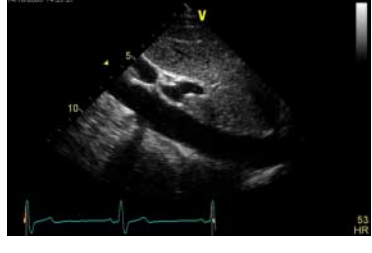

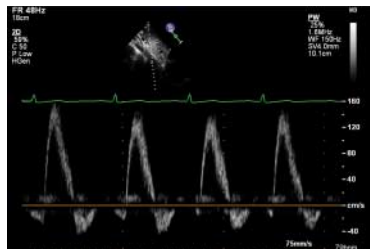

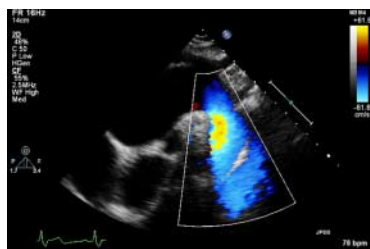
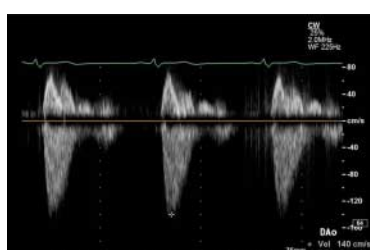
View (modality)	Measurement	Explanatory note	Image
SC4C (2D)		Four chamber structures, atrial septum	
SC4C (CFM)		Atrial septum  Consider reducing Nyquist limit to detect low velocity flow	
SCSAX (2D)		IVC, hepatic vein (modified view)	
SCSAX (MM)	Size and respiratory variation (‘sniff’)	IVC just proximal to hepatic vein	
SCSAX (2D)		SAX structures  Atrial septum, TV, RVOT, PV, PA's	
SCSAX (2D)		Abdominal aorta (modified view)	



Table 1 Continued

View (modality)	Measurement	Explanatory note	Image
SCSAX (PW)		Hepatic veins	
SCSAX (PW)		Abdominal aorta	
SSN (2D)		Arch	
SSN (CFM)		Arch, RPA, look for abnormal colour flow	
SSN (CW)	$V_{max}$	Descending aorta with imaging probe, if good alignment with jet  Descending aorta with non imaging probe, if poor jet alignment with imaging probe	

## Abbreviations

### Views

A2C	Apical two chamber
A4C	Apical four chamber
A5C	Apical five chamber
A3C	Apical long axis or apical three chamber
PLAX	Parasternal long axis
PSAX	Parasternal short axis
SC	Subcostal
SSN	Suprasternal
Modality	
CFM	Colour flow Doppler
CW	Continuous wave Doppler
PW	Pulse wave Doppler
TDI	Tissue Doppler imaging

### Measurement and explanatory text

Ao	Aorta
AV	Aortic valve
BSA	Body surface area
DT	Deceleration time
IVC	Inferior vena cava
IVSd	Interventricular septal width in diastole
LA	Left atrium
LLPV	Left lower pulmonary vein
LPA	Left pulmonary artery
LUPV	Left upper pulmonary vein
LV	Left ventricle
LVIDd/s	Left ventricular internal dimension in diastole and systole
LVOT	Left ventricular outflow tract
LVPWd	Left ventricular posterior wall width in diastole
MAPSE	Mitral annular plane systolic excursion
MV	Mitral valve
PA	Pulmonary artery
PAP	Pulmonary artery pressure
PHT	Pressure half-time
PR	Pulmonary regurgitation
PS	Pulmonary stenosis
PV	Pulmonary valve
RA	Right atrium
RLPV	Right lower pulmonary vein
RUPV	Right upper pulmonary vein
RV	Right ventricle
RVIDd	Right ventricular cavity diameter in diastole
RWMA	Regional wall motion abnormality
RVOT	Right ventricular outflow tract
RVOTd	Right ventricular outflow tract dimension
STJ	Sinotubular junction
SVol	Stroke volume
TAPSE	Tricuspid annular plane systolic excursion
TR	Tricuspid regurgitation
TV	Tricuspid valve
V <sub>max</sub>	Maximum velocity
VSD	Ventricular septal defect
VTI	Velocity time integral

## Appendix 1 Minimum dataset measurements.

### 1. Views to be obtained:

PLAX	Parasternal long axis
PLAX	Tilted RV inflow
PSAX	Parasternal short axis: base, mid, apex
A4C	Apical four chamber

### Modified A4C for RV

A2C	Apical two chamber
A5C	Apical five chamber
SC	Subcostal
SSN	Suprasternal

### 2. Recorded and measured where appropriate

LVIDd/s	Left ventricular internal dimension in diastole and systole
IVSd	Interventricular septal width in diastole
LVPWd	Left ventricular posterior wall width in diastole
LA	Left atrial dimension in PLAX
Sinus	Sinus of valsalva
TR V <sub>max</sub>	Tricuspid regurgitation maximal velocity
LVEDvol d/s	Left ventricular end-diastolic and systolic volume (biplane/3D)
LVEF	Left ventricular ejection fraction
LA volume	Left atrial volume at end-ventricular systole (area-length/biplane)
TAPSE	Tricuspid annular plane systolic excursion
Mitral E/A	Mitral valve maximal velocity early and atrial filling
e'	Lateral and/or septal early myocardial relaxation velocity
AV V <sub>max</sub>	Maximal aortic velocity on CW
RV base	Right ventricular basal dimension in diastole
IVC dimension	Estimation of RA pressure

### Declaration of interest

The authors declare that there is no conflict of interest that could be perceived as prejudicing the impartiality of this guideline.

### Funding

This guideline did not receive any specific grant from any funding agency in the public, commercial or not-for-profit sector.

Received in final form 13 February 2015

Accepted 17 February 2015