

GUIDELINES AND RECOMMENDATIONS

A systematic approach to echocardiography in hypertrophic cardiomyopathy: a guideline protocol from the British Society of Echocardiography

Nicola Smith*, Richard Steeds†, Navroz Masani¹, Julie Sandoval², Gill Wharton³, Jane Allen³, John Chambers⁴, Richard Jones⁵, Guy Lloyd⁶, Bushra Rana⁷, Kevin O’Gallagher⁸, Richard Wheeler¹ and Vishal Sharma⁹

Queen Elizabeth Hospital, University Hospital Birmingham NHS Foundation Trust, Birmingham, UK

¹University Hospital of Wales, Cardiff, UK

²InHealth Echotech, Hampshire, UK

³York Teaching Hospital NHS Foundation Trust, York, UK

⁴Guy’s and St Thomas’ NHS Foundation Trust, London, UK

⁵Portsmouth Hospitals NHS Trust, Portsmouth, UK

⁶Eastbourne District General Hospital, Eastbourne, UK

⁷Cardiology Department, Papworth Hospital, Cambridge, UK

⁸King’s College Hospital NHS Foundation Trust, London, UK

⁹Royal Liverpool and Broadgreen University Hospitals, Liverpool, UK

* (N Smith is the lead author)

† (R Steeds is the Guidelines Chair)

Correspondence should be addressed to V Sharma
Email
vishal.sharma@rlbuht.nhs.uk

Abstract

Hypertrophic cardiomyopathy (HCM) is a relatively common inherited cardiac condition with a prevalence of approximately one in 500. It results in otherwise unexplained hypertrophy of the myocardium and predisposes the patient to a variety of disease-related complications including sudden cardiac death. Echocardiography is of vital importance in the diagnosis, assessment and follow-up of patients with known or suspected HCM. The British Society of Echocardiography (BSE) has previously published a minimum dataset for transthoracic echocardiography, providing the core parameters necessary when performing a standard echocardiographic study. However, for patients with known or suspected HCM, additional views and measurements are necessary. These additional views allow more subtle abnormalities to be detected or may provide important information in order to identify patients with an adverse prognosis. The aim of this Guideline is to outline the additional images and measurements that should be obtained when performing a study on a patient with known or suspected HCM.

Key Words

- ▶ hypertrophic cardiomyopathy
- ▶ transthoracic echocardiography
- ▶ 2D echocardiography
- ▶ guidelines

Introduction

1.1 The British Society of Echocardiography (BSE) Education Committee has previously published a minimum dataset for a standard adult transthoracic echocardiogram (1). This Guideline specifically

states that the minimum dataset is usually sufficient only when the echocardiographic study is entirely normal. The aim of the BSE Education Committee is to publish a series of appendices to cover specific pathologies supporting this minimum dataset.

1.2 The intended benefits of such supplementary recommendations are to:

- Support cardiologists and echocardiographers to develop local protocols and quality control programs for adult transthoracic study.
- Promote quality by defining a set of descriptive terms and measurements, in conjunction with a systematic approach to performing and reporting a study in specific disease states.
- Facilitate the accurate comparison of serial echocardiograms performed in patients at the same or different sites.

1.3 This Guideline gives recommendations for the image and analysis dataset required in patients

either being assessed for, or with a known diagnosis of hypertrophic cardiomyopathy (HCM). The views and measurements are supplementary to those outlined in the minimum dataset and are given assuming that a full study will be performed in all patients.

1.4 When the condition or acoustic windows of the patient prevent the acquisition of one or more components of the supplementary dataset, or when measurements result in misleading information (e.g. off-axis measurements), this should be stated.

1.5 This document is a guideline for echocardiography in HCM and will be updated in accordance with changes directed by publications or changes in practice ([Table 1](#)).

Table 1 Continued





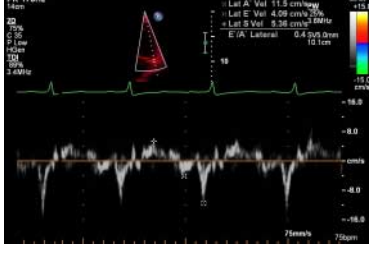
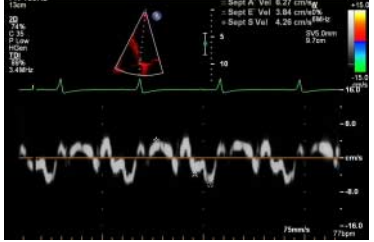
View (modality)	Measurement	Explanatory note	Image
Modified PSAX (2D and PW/CW)	RV wall thickness and RVOT forward flow velocities	Modify both the RV inflow and outflow to assess for RVH and RVOT obstruction. RVH present if >0.5 cm	
Modified A4C (2D)	RV wall thickness	If clear images can be obtained, measure RV wall thickness. Otherwise measurement from PLAX and subcostal views is preferred. RVH present if >0.5 cm	
A4C and A2C (2D)	LA volume	Index LA volume to BSA (4)	
A4C (CFM)	Aetiology and severity of mitral regurgitation	If SAM is present, MR may be eccentric and is usually mid/late systolic	
A4C (PW TDI)	Systolic (s'), early (e') and atrial (a') relaxation velocities at anterolateral LV annulus	Reduction in s' or e' velocities below normal range for age and sex (5) Assess for elevated LVEDp by measuring E/e'. Average septal and lateral velocities for e'. Abnormal if >10 (4)	
A4C (PW TDI)	Systolic (s'), early (e') and atrial (a') relaxation velocities at inferoseptal LV annulus	Reduction in Sa or Ea velocities below normal range for age and sex (5) Assess for elevated LVEDp by measuring E/e'. Average septal and lateral velocities for e'. Abnormal if >10 (4)	

Table 1 Continued

View (modality)	Measurement	Explanatory note	Image
A5C and A3C (CFM)		Locate turbulent flow both within the LV cavity and the LVOT	
A5C and A3C (PW/CW)	Quantify LVOT/LV intracavity dynamic flow gradient	Sample PW Doppler throughout the LV cavity, paying particular attention to areas with turbulent flow. HPRF/CW Doppler may be appropriate if aliasing occurs. Take care not to include MR jet in sample volume. A Valsalva manoeuvre should be performed in the sitting and semi-supine position (and then on standing if no gradient is produced) to assess dynamic LVOT gradients. The peak gradient (rest or Valsalva) should be recorded. In addition, exercise stress echocardiography should be considered in patients with LVOT gradients < 50 mmHg at rest (with or without Valsalva) (3)	
A2C (PW TDI)	Systolic (s'), early (e') and atrial (a') relaxation velocities at inferior LV annulus	Reduction in s' or e' velocities below normal range for age and sex (5)	
A2C (PW TDI)	Systolic (s'), early (e') and atrial (a') relaxation velocities at anterior LV annulus	Reduction in s' or e' velocities below normal range for age and sex (5)	

Abbreviations

Views

A2C	Apical two chamber
A4C	Apical four chamber
A5C	Apical five chamber
A3C	Apical three chamber or apical long axis

PLAX	Parasternal long axis
PSAX	Parasternal short axis
SC	Subcostal
SSN	Suprasternal

Modality

CFM	Colour flow Doppler
CW	Continuous-wave Doppler
PW	Pulse wave Doppler
TDI	Tissue Doppler imaging

Measurement and explanatory text

a'	Lateral and/or septal late annular relaxation velocity
Ao	Aorta
ASH	Asymmetrical septal hypertrophy
AV	Aortic valve
BSA	Body surface area
DT	Deceleration time
e'	Lateral and/or septal early annular relaxation velocity
HCM	Hypertrophic cardiomyopathy
HPRF	High pulse repetition frequency
IVC	Inferior vena cava
IVSd	Interventricular septal width in diastole
LA	Left atrium
LLPV	Left lower pulmonary vein
LPA	Left pulmonary artery
LUPV	Left upper pulmonary vein
LV	Left ventricle
LVEDp	Left ventricular end-diastolic pressure

LVIDd/s	Left ventricular internal dimension in diastole and systole
LVOT	Left ventricular outflow tract
LVPWd	Left ventricular posterior wall width in diastole
MAPSE	Mitral annular plane systolic excursion
MR	Mitral regurgitation
MV	Mitral valve
PA	Pulmonary artery
PAP	Pulmonary artery pressure
PHT	Pressure half-time
PR	Pulmonary regurgitation
PS	Pulmonary stenosis
PV	Pulmonary valve
RA	Right atrium
RLPV	Right lower pulmonary vein
RUPV	Right upper pulmonary vein
RV	Right ventricle
RVH	Right ventricular hypertrophy
RVIDd	Right ventricular cavity diameter in diastole
RWMA	Regional wall motion abnormality
RVOT	Right ventricular outflow tract
RVOTd	Right ventricular outflow tract dimension
s'	Lateral and/or septal systolic annular velocity
SAM	Systolic anterior motion
STJ	Sinotubular junction
SVol	Stroke volume
TAPSE	Tricuspid annular plane systolic excursion
TR	Tricuspid regurgitation
TV	Tricuspid valve
Vmax	Maximum velocity
VSD	Ventricular septal defect
VTI	Velocity time integral

Declaration of interest

This manuscript was prepared by the British Society of Echocardiography Education Committee. The authors declare that there is no conflict of interest that could be perceived as prejudicing the impartiality of this guideline.

Funding

This guideline did not receive any specific grant from any funding agency in the public, commercial or not-for-profit sector.

References

- 1 Wharton G, Steeds R, Allen J, Phillips H, Jones R, Kanagala P, Lloyd G, Masani N, Mathew T, Oxborough D *et al*. 2015 A minimum dataset for a standard adult transthoracic echocardiogram: a guideline protocol from the British Society of Echocardiography. *Echo Research and Practice* **2** G9–G24. (doi:10.1530/ERP-14-0079)
- 2 Maron BJ, McKenna WJ, Danielson GK, Kappenberger LJ, Kuhn HJ, Seidman CE, Shah PM, Spencer WH, III, Spirito P, Ten Cate FJ *et al* 2003 American College of Cardiology/European Society of Cardiology clinical expert consensus document on hypertrophic cardiomyopathy. A report of the American College of Cardiology Foundation Task Force on Clinical Expert Consensus Documents and the European Society of Cardiology Committee for Practice Guidelines. *Journal of the American College of Cardiology* **42** 1687–1713. (doi:10.1016/S0735-1097(03)00941-0)
- 3 Elliott PM, Anastakis A, Borger MA, Borggrefe M, Cecchi F, Charron P, Hagege AA, Lafont A, Limongelli G, Mahrholdt H *et al* 2014 ESC Guidelines on diagnosis and management of hypertrophic cardiomyopathy: the Task Force for the Diagnosis and Management of Hypertrophic Cardiomyopathy of the European Society of Cardiology (ESC). *European Heart Journal* **35** 2733–2779. (doi:10.1093/eurheartj/ehu199)
- 4 Masani N, Wharton G, Allen J, Chambers J, Graham J, Jones R, Rana B 2011 British Society of Echocardiography Guidelines for Chamber Quantification; http://www.bsecho.org/media/40506/chamber-final-2011_2_.pdf
- 5 Nagueh SF, Appleton CP, Gillebert TC, Marino PN, Oh JK, Smiseth OA, Waggoner AD, Flachskampf FA, Pellikka PA & Evangelista A 2009 Recommendations for the evaluation of left ventricular diastolic function by echocardiography. *Journal of the American Society of Echocardiography* **22** 107–133. (doi:10.1016/j.echo.2008.11.023)

Received in final form 8 February 2015

Accepted 11 February 2015